

Abdominal Aortic and Junctional Tourniquet Controls Hemorrhage From a Gunshot Wound of the Left Groin

John Croushorn, MD, FACEP

ABSTRACT

“Junctional hemorrhage” is defined as bleeding from the areas at the junction of the trunk and its appendages. This is an important cause of potentially preventable deaths on the battlefield and a difficult condition to treat in the civilian prehospital setting. Having a solution to definitively treat the condition decreases the mortality and morbidity of these injuries. The Abdominal Aortic and Junctional Tourniquet™ is (1) a Food and Drug Administration–cleared device that is currently indicated for pelvic, inguinal, and axillary bleeding; (2) the only junctional tourniquet with an indication for pelvic bleeding; (3) the only junctional tourniquet reported with a successful axillary use; and (4) effective at lower tissue pressures than other junctional tourniquets available.

KEYWORDS: *Abdominal Aortic and Junctional Tourniquet, hemorrhage, gunshot wound*

Introduction

Junctional hemorrhage is defined as bleeding from the areas at the junction of the trunk and its appendages. This is an important cause of potentially preventable deaths on the battlefield and a difficult condition to treat in the civilian prehospital setting. Having a solution to definitively treat the condition decreases the mortality and morbidity resulting from these injuries.

The U.S. military has identified junctional hemorrhage control as an important capability gap in military medicine.¹ One recent review of battle casualties found that 21% of casualties who died of wounds had junctional bleeding, possibly amenable to a truncal tourniquet.² The Abdominal Aortic Tourniquet™ (AAT) was applied to a Soldier with multiple life-threatening injuries in Afghanistan in 2013.^{3,4} The AAT rapidly stopped the bleeding and freed the hands of medical providers to perform other lifesaving prehospital interventions on the wounded patient. The AAT was applied to an axillary wound in the patient who had lost 6 cm of his axillary artery. It successfully stopped the hemorrhage and allowed the patient to be resuscitated and to undergo

surgery. The patient successfully survived the surgery and recovered to walk out of the hospital.⁵

In December 2013, the AAT was renamed Abdominal Aortic and Junctional Tourniquet™ (AAJT) (<http://www.compressionworks.net>) and received new indications from the U.S. Food and Drug Administration to treat pelvic bleeding and bleeding in the inguinal region and axilla. The device placement also was changed to allow for individual groin application and axillary placement, as outlined in the previously described case study.

The present case report describes an on-label use of the AAJT in the groin and demonstrates its safety and effectiveness in stopping hemorrhage from a challenging wound.

Case Presentation

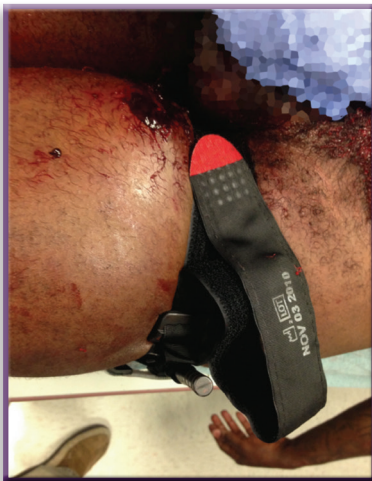A 21-year-old man was driven to the main entrance of the emergency department. The patient had sustained three gunshot wounds to his lower extremities. His right leg sustained two of these wounds, and his left leg sustained the third wound. The right leg wounds were not bleeding: They were to the right ankle and right mid-inner thigh. The latter had only one wound, and radiography demonstrated a retained bullet. The left leg wound was to the proximal thigh. A small entry wound was located laterally, and a large exit wound was located in the proximal medial thigh. A large amount of blood was noted in the patient's pants. The proximal left thigh wound was bleeding profusely when exposed. The patient was lethargic. He was brought to a resuscitation room, and direct manual pressure was applied to the left groin wound to control the hemorrhage.

The diaphoretic patient was arousable but confused. The primary emergency physician focused on hemorrhage control, and a partner focused on assessing the airway. Monitoring at that time showed a heart rate of 150 beats/min (bpm); however, blood pressure was too low to be detected when measurement was attempted. A thready carotid pulse was noted. With tachycardia, unobtainable blood pressure, and lethargic state, the

patient was assessed to be in hemorrhagic shock. Four units of emergent O-negative packed red blood cells (PRBCs) were requested; they were at the bedside 12 minutes after the patient's arrival.

A Combat Application Tourniquet® (CAT) (North American Rescue LLC; <http://www.narescue.com>) was applied proximal to the wound, and bleeding stopped (Figure 1). After the second unit of PRBCs and the first liter of normal saline were transfused, the patient became more alert and began complaining of the discomfort from the CAT tourniquet. His systolic blood pressure was measured at 75mmHg. His heart rate decreased to 130 bpm. At this time, bleeding was noted from the inner proximal thigh wound on the left leg. An attempt to place a second CAT tourniquet was made; however, the first CAT tourniquet abutted the perineum, and there was no room for a second tourniquet to be placed above the first.

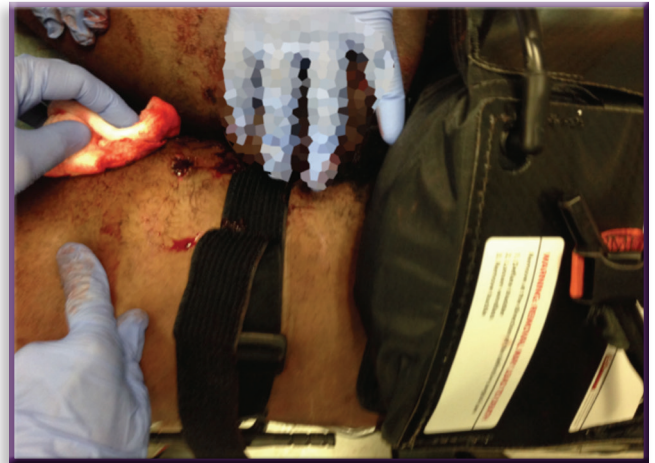Figure 1 Initial use of the CAT in the emergency department. The proximal femoral wound is seen with initial hemostasis noted.



The AAJT was applied by the primary emergency physician around the hips, with the bladder against the left groin (Figure 2). The belt was tightened, the windlass then was tightened and secured, and the bladder was inflated until the manometer showed green, indicating 250mmHg pressure. The CAT was kept in place, but the tension was released. The wounds were reassessed, and no blood loss was found to have occurred. The patient commented that the AAJT was more comfortable than the CAT.

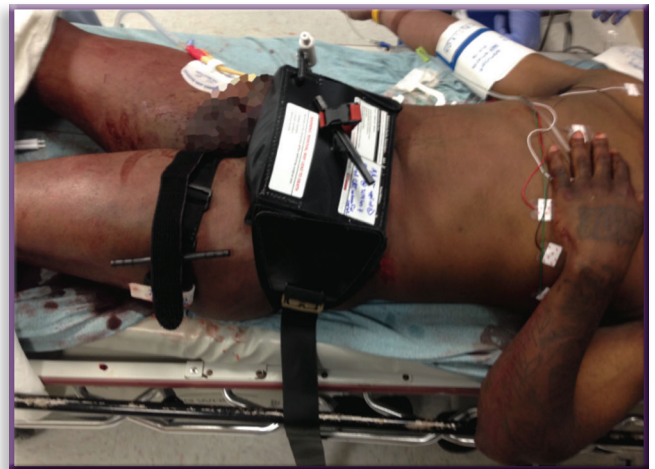
The patient was assessed surgically and thought to be stable enough to transfer to a Level I trauma center for further resuscitative measures and vascular repair. Before transfer, the patient received a third and fourth unit of emergent O-negative PRBCs. He received a second liter of normal saline. At the time of transfer, his blood pressure was 101/50mmHg, and he had a pulse rate of 102. He was alert and oriented. The patient was

Figure 2 The AAJT is applied to the left groin. The CAT has been left in place but loosened. The wound is seen just to the left of the CAT.



transferred from the emergency department to the Level I trauma center via Advanced Life Support (ALS) ambulance with a nurse (Figure 3). Throughout transport and movement to the trauma unit, the AAJT remained inflated, and no blood loss was noted from the proximal left leg wound.

Figure 3 The patient is prepared for transport to the Level 1 trauma center. The AAJT is applied to the left groin. The CAT is loose but in place. The patient is awake and hemodynamically stable.



On vascular surgery, a transection of the left deep femoral artery was noted. The artery was ligated. No other significant arterial injury was found. The patient recovered and walked out of the hospital on postoperative day 3. Posthospitalization follow-up has continued to show no complications related to the use of the AAJT.

Lessons Learned

The AAJT was quickly applied over the hips and positioned over the groin. Slack removal is essential for

optimal use of any circumferential tourniquet. Once the slack was removed, the windlass was tightened and secured. The device was fully inflated to the green indicator, which measures pressures of 250–300mmHg. There was no blood flow from the wound at an inflation pressure below 250mmHg. In the human research for FDA clearance, the AAJT was noted to be effective in the inguinal region at lower pressures than the original abdominal placement. The pressure for occlusion of blood flow to the femoral artery was 148.5mmHg in 100% of the subjects. There may be benefits in a gauge that indicates this lower pressure during application as sufficient for the groin. Likewise, the human research for the axillary placement showed 100% effectiveness on all patients at 168mmHg.

The AAJT is (1) an FDA-cleared device that is currently indicated for pelvic, inguinal, and axillary bleeding; (2) the only junctional tourniquet with an indication for pelvic bleeding; (3) the only junctional tourniquet reported with a successful axillary use; and (4) effective at lower tissue pressures than other junctional tourniquets available.

Disclosure

Dr. Croushorn is one of the inventors of the AAJT and president of Compression Works LLC (<http://www.compressionworks.net/>), which developed and manufactures the device.

.compressionworks.net/), which developed and manufactures the device.

References

1. Kragh JF Jr, Murphy C, Dubick MA, et al. New tourniquet device concepts for battlefield hemorrhage control. *US Army Med Department J.* 2011;38–48, 2011.
2. Eastridge BJ, Hardin M, Cantrell J, et al. Died of wounds on the battlefield: causation and implications for improving combat casualty care. *J Trauma Acute Care Surg*, 2011; 71:S4–S8.
3. Case Report: Abdominal Aortic Tourniquet use in Afghanistan. *J Spec Oper Med.* 2013;13:1–2.
4. Croushorn J, Calloway D. Abdominal Aortic Tourniquet Commentary. *J Spec Oper Med.* 2013;13:3.
5. Case Report: Abdominal Aortic Tourniquet controls junctional hemorrhage from a gunshot wound of the axilla. *J Spec Oper Med.* 2013;13:1–4.

Dr. Croushorn has been involved in hemorrhage control research since 2005. He is a board-certified emergency physician who lives in Birmingham, AL. He was a former command surgeon, Task Force 185, OIF 2004. E-mail: compressworks@gmail.com.

THE ONLY JUNCTIONAL TOURNIQUET TO SAVE LIFE IN UPPER AND LOWER JUNCTIONAL BLEEDING



The Abdominal Aortic & Junctional Tourniquet

The Only Device Indicated for Pelvic Junctional Bleeding

The Abdominal Aortic & Junctional Tourniquet™ (AAJT) is the only junctional tourniquet approved to treat hemorrhage in the pelvis, a common complication of lower junctional injuries.

- Pelvic Bleeding
- Stabilize the Pelvis
- Inguinal Bleeding
- Axilla Bleeding
- Safest Junctional Tourniquet (JxnTQ)
- Only JxnTQ with Human Safety Data
- Best JxnTQ for confined space rescue
- "The one that works"

Designed by Special Operations personnel who have confronted the problem of junctional hemorrhage.

Hemorrhage Stops Here™

www.compressionworks.net
www.speeroptech.com

NSN#: 6515-01-616-4999
TOLL FREE: 1-888-427-5231



